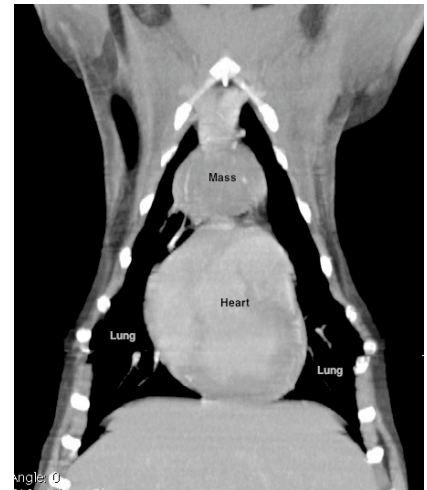


Thymoma Tumors

Thymoma is a tumor that arises from cells of the thymus, an organ present in all mammals responsible for normal immune cell (T-lymphocyte) maturation. The normal thymus is located in the cranial (anterior) mediastinum, often immediately in front of the heart within the chest cavity. These tumors are most common in older animals, and clinical signs associated with this type of tumor are often non-specific (i.e. lethargy, weight loss, etc) and rarely associated with a cough or respiratory difficulty until they grow large in size. Additionally, thymomas can also cause secondary or “paraneoplastic” metabolic and immune system dysfunction such as elevation in serum calcium and autoimmune myasthenia gravis.

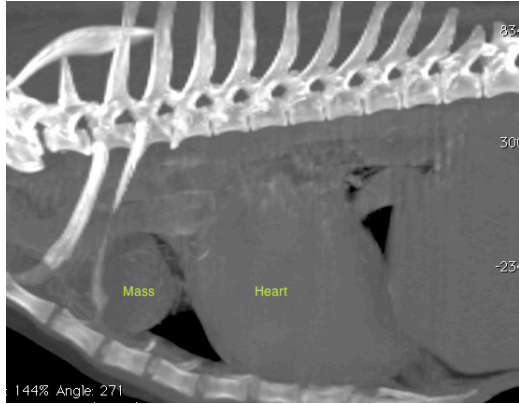


A preliminary diagnosis of thymoma is often made based on the location of the tumor and aspiration cytology. The importance of aspiration cytology cannot be understated because several different tumor types including lymphoma, a non-surgical disease, can appear very similar on imaging studies and can have identical clinical signs. Other types of tumors that occur less commonly in this region include thyroid carcinoma, heart base tumors and others which are also important to diagnose prior to treatment as the prognosis associated with these other tumor types are often not as favorable. Compared to many of the other potential tumor types that can occur in this region, thymoma carries a relatively good prognosis with treatment.

The treatment of choice for both canine and feline thymoma is surgery. In patients with relatively small masses, excision of the mass can be performed thoroscopically as a minimally invasive manor; a procedure that is offered at Aspen Meadow Veterinary Specialists. For larger or more invasive masses, thoracotomy (opening of the chest either through the sternum (median sternotomy approach) or in between the ribs (intercostal approach) is often required.

The majority of thymoma in dogs and cats are well encapsulated and amenable to surgery. Unfortunately, ~30% of thymomas are more invasive into the surrounding structures within the chest and are not easily amenable to surgery. Pre-operative advanced imaging with a CT scan can aid in determining the invasiveness of a particular thymoma as well as help rule out other diseases that may be concurrently present. As such, pre-operative CT scan is recommended but not required.

With surgical excision, the average survival time in dogs and cats is 2 and 5 years, respectively. In both species, most animals ultimately die of unrelated causes without recurrence of their original tumor. In one study looking at



results of surgical excision of thymoma a recurrence rate of 10% in dogs and 20% in cats.

If surgery is not an option either as a result of the mass being too invasive or for patient or owner reasons, alternative therapies such as chemotherapy and/or radiation therapy have been employed for both canine and feline thymoma with variable results. One study looking at a combination of chemo and radiation therapy found an overall response rate in dogs and cats to be 75% but duration of response was relatively short lived and most pets died of disease recurrence. The average survival of dogs and cats treated with radiation therapy with or without chemotherapy in that study was 8 and 22 months, respectively.

If you have any further questions regarding canine or feline thymoma, or animal cancer in general, please feel free to contact us at 303-678-8844 or email jperry@aspenmeadowvet.com.